

Management of Epistaxis

CORRY J. KUCIK, LT, MC, USN, and TIMOTHY CLENNEY, CDR, MC, USN
Naval Hospital Jacksonville, Jacksonville, Florida

Family physicians frequently encounter patients with epistaxis (nasal bleeding). In rare cases, this condition may lead to massive bleeding and even death. Although epistaxis can have an anterior or posterior source, it most often originates in the anterior nasal cavity. A directed history and physical examination generally determine the cause of the bleeding. Both local and systemic processes can play a role in epistaxis. Nasal bleeding usually responds to first-aid measures such as compression. When epistaxis does not respond to simple measures, the source of the bleeding should be located and treated appropriately. Treatments to be considered include topical vasoconstriction, chemical cautery, electrocautery, nasal packing (nasal tampon or gauze impregnated with petroleum jelly), posterior gauze packing, use of a balloon system (including a modified Foley catheter), and arterial ligation or embolization. Topical or systemic antibiotics should be used in selected patients. Hospital admission should be considered for patients with significant comorbid conditions or complications of blood loss. Referral to an otolaryngologist is appropriate when bleeding is refractory, complications are present, or specialized treatment (balloon placement, arterial ligation, angiographic arterial embolization) is required. (*Am Fam Physician* 2005;71:305-11, 312. Copyright© 2005 American Academy of Family Physicians.)

► **Patient information:** A handout on nosebleeds, written by the authors of this article, is provided on page 312.

See page 225 for definitions of strength-of-recommendation labels.

Epistaxis, or nasal bleeding, has been reported to occur in up to 60 percent of the general population.¹⁻³ The condition has a bimodal distribution, with incidence peaks at ages younger than 10 years and older than 50 years. Epistaxis appears to occur more often in males than in females.^{1,4}

Epistaxis is common, and affected persons

usually do not seek medical attention, particularly if the bleeding is minor or self-limited. In rare cases, however, massive nasal bleeding can lead to death.⁵⁻⁷

Anatomy

The rich vascular supply of the nose originates from the ethmoid branches of the internal carotid arteries and the facial and internal maxillary divisions of the external carotid arteries.⁵ Although nasal circulation is complex (*Figure 1*), epistaxis usually is described as either anterior or posterior bleeding. This simple distinction provides a useful basis for management.

Most cases of epistaxis occur in the anterior part of the nose, with the bleeding usually arising from the rich arterial anastomoses of the nasal septum (Kiesselbach's plexus). Posterior epistaxis generally arises from the posterior nasal cavity via branches of the sphenopalatine arteries.⁸ Such bleeding usually occurs behind the posterior portion of the middle turbinate or at the posterior superior roof of the nasal cavity.

In most cases, anterior bleeding is clinically obvious. In contrast, posterior bleeding may be asymptomatic or may present insidiously as nausea, hematemesis, ane-

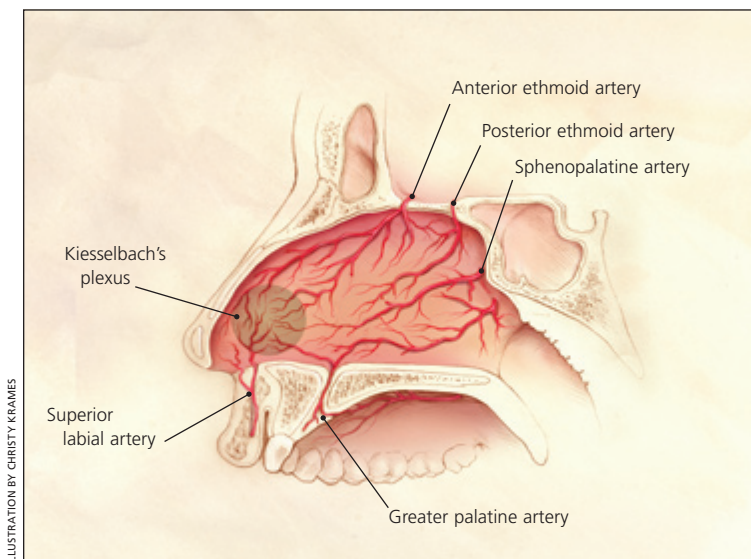


Figure 1. Vascular anatomy of nasal septal blood supply.

Strength of Recommendations

Key clinical recommendation	Label	References
If local treatments fail to stop anterior bleeding, the anterior nasal cavity should be packed from posterior to anterior with ribbon gauze impregnated with petroleum jelly or antibiotic ointment.	C	5, 9
Based on one study, chemical cautery (silver nitrate sticks) can be used for simple anterior epistaxis because it has efficacy and complication rates similar to electrocautery.	C	14
Because of the possibility of toxic shock syndrome with prolonged nasal packing, use of a topical antistaphylococcal antibiotic ointment on the packing materials has been recommended.	C	10, 12
Either ribbon gauze packing or nasal tampons can be used for packing; one study found no significant difference in patient comfort or efficacy.	B	15

A = consistent, good-quality patient-oriented evidence; B = inconsistent or limited-quality patient-oriented evidence; C = consensus, disease-oriented evidence, usual practice, opinion, or case series. See page 225 for more information.

mia, hemoptysis, or melena. Infrequently, larger vessels are involved in posterior epistaxis and can result in sudden, massive bleeding.

Etiology

Most causes of nasal bleeding can be identified readily through a directed history and physical examination. The patient should be asked about the initial presentation of the bleeding, previous bleeding episodes and their treatment, comorbid conditions, and current medications, including over-the-counter medicines and herbal and home remedies. Although the differential diagnosis should include both local and systemic causes (Table 1),^{1,5,9} environmental factors such as humidity and allergens also must be considered.^{5,10} Often, no cause for the bleeding is identified.

Management

GENERAL APPROACH

Initial management includes compression of the nostrils (application of direct pressure to the septal area) and plugging of the affected nostril with gauze or cotton that has been soaked in a topical decongestant. Direct pressure should be applied continuously for at least five minutes, and for up to 20 minutes. Tilting the head forward prevents blood from pooling in the posterior pharynx, thereby avoiding nausea and airway obstruction. Hemodynamic stability and

Initial management of epistaxis includes compression of the nostrils and plugging of the affected nostril with gauze or cotton that has been soaked in a topical decongestant.

TABLE 1
Common Causes of Epistaxis

Local causes

Chronic sinusitis
Epistaxis digitorum (nose picking)
Foreign bodies
Intranasal neoplasm or polyps
Irritants (e.g., cigarette smoke)
Medications (e.g., topical corticosteroids)
Rhinitis
Septal deviation
Septal perforation
Trauma
Vascular malformation or telangiectasia

Systemic causes

Hemophilia
Hypertension
Leukemia
Liver disease (e.g., cirrhosis)
Medications (e.g., aspirin, anticoagulants, nonsteroidal anti-inflammatory drugs)
Platelet dysfunction
Thrombocytopenia

Information from references 1, 5, and 9.

airway patency should be confirmed. Fluid resuscitation should be initiated if volume depletion is suspected.

Every attempt should be made to locate the source of bleeding that does not respond to simple compression and nasal plugging. The examination should be performed in a well-lighted room, with the patient seated and clothing protected by a sheet or gown.

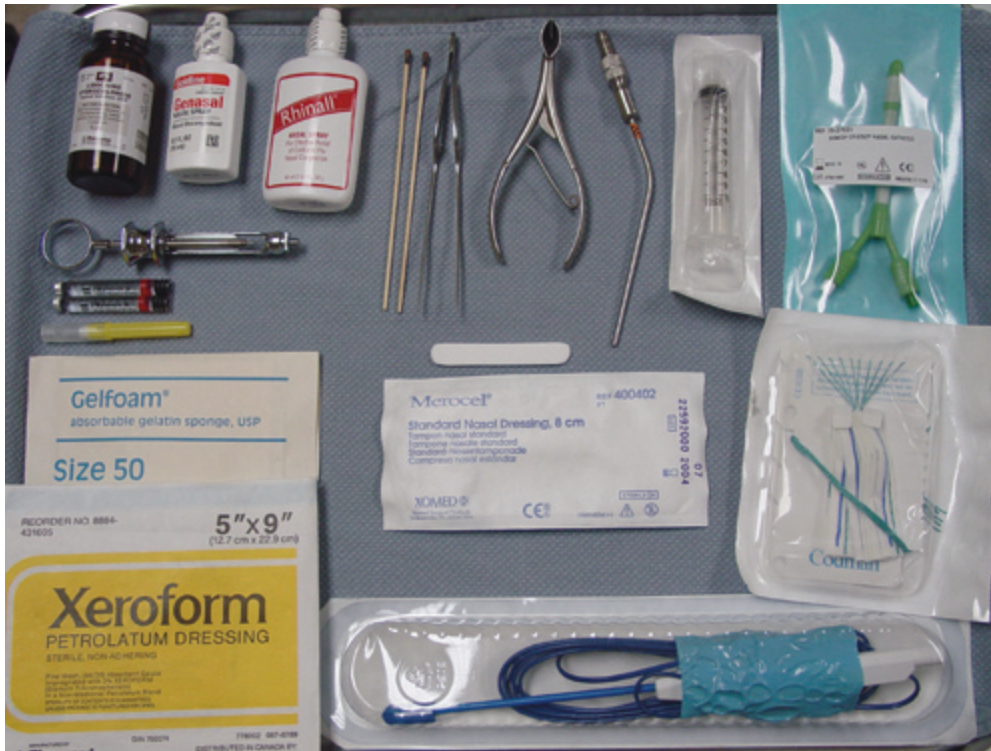


Figure 2. Typical contents of an epistaxis tray. *Top row:* nasal decongestant sprays and local anesthetic, silver nitrate cautery sticks, bayonet forceps, nasal speculum, Frazier suction tip, posterior double balloon system and syringe for balloon inflation. *Bottom row:* Packing materials, including nonadherent gauze impregnated with petroleum jelly and 3 percent bismuth tribromophenolate (Xeroform), Merocel, Gelfoam, and suction cautery.

The physician should wear gloves and other appropriate protective equipment (e.g., surgical mask, safety glasses). A headlamp or head mirror and a nasal speculum should be used for optimal visualization.

An epistaxis tray can be created using common supplies and a few specialized instruments (*Figure 2*). Clots and foreign bodies in the anterior nasal cavity can be removed with a small (Frazier) suction tip, irrigation, forceps, and cotton-tipped applicators.

When posterior bleeding is suspected, the general location of the source should be determined. This step is important because different arteries supply the floor and roof of the posterior nasal cavity; therefore, selective ligation may be required.^{5,11}

Diffuse oozing, multiple bleeding sites, or recurrent bleeding may indicate a systemic process such as hypertension, anticoagulation, or coagulopathy. In such cases, a hematologic evaluation should be performed.

Appropriate tests include a complete blood count, anticoagulant levels, a prothrombin time, a partial thromboplastin time, a platelet count and, if indicated, blood typing and crossmatching.^{9,12}

Although most patients with epistaxis can be treated as outpatients, hospital admission and close observation should be considered for elderly patients and patients with posterior bleeding or coagulopathy. Admission also may be prudent for patients with complicating comorbid conditions such as coronary artery disease, severe hypertension, or significant anemia.

ANTERIOR EPISTAXIS

If a single anterior bleeding site is found, vasoconstriction should be attempted with topical application of a 4 percent cocaine solution or an oxymetazoline or phenylephrine solution.

Diffuse oozing, multiple bleeding sites, or recurrent bleeding may indicate a systemic process such as hypertension, anticoagulation, or coagulopathy.

For bleeding that is likely to require more aggressive treatment, a local anesthetic, such as a 4 percent cocaine solution or tetracaine or lidocaine (Xylocaine) solution, should be used. Adequate anesthesia should be obtained before treatment proceeds.

Intravenous access should be obtained in difficult cases, especially when anxiolytic medications are to be used.

Cotton pledgets soaked in vasoconstrictor and anesthetic should be placed in the anterior nasal cavity, and direct pressure should be applied at both sides of the nose

for at least five minutes. Then the pledgets can be removed for reinspection of the bleeding site. If this measure is unsuccessful, chemical cautery can be attempted using a silver nitrate stick applied directly to the bleeding site for approximately 30 seconds.⁵ Other treatment

options include hemostatic packing with absorbable gelatin foam (Gelfoam) or oxidized cellulose (Surgicel). Use of desmopressin spray (DDAVP) may be considered in a patient with a known bleeding disorder.^{5,13}

Larger vessels generally respond more readily to electrocautery. However, electrocautery must be performed cautiously to avoid excessive destruction of healthy surrounding tissues. Note that use of electrocautery on both sides of the septum may increase the risk of septal perforation.⁹

Interestingly, at least one study¹⁴ found no difference in efficacy or complication rate between chemical cautery (silver nitrate stick) and electrocautery.

If local treatments fail to stop anterior bleeding, the anterior nasal cavity should be packed, from posterior to anterior, with ribbon gauze impregnated with petroleum jelly or polymyxin B-bacitracin zinc-neomycin (Neosporin) ointment. Nonadherent gauze impregnated with petroleum jelly and 3 percent bismuth tribromophenate (Xeroform) also works well for this purpose.^{5,9} Bayonet forceps and a nasal speculum are used to approximate the accordion-folded layers of the gauze, which should extend as far back into the nose as possible. Each layer should be pressed down firmly before the next layer is inserted (*Figure 3*). Once the cavity has been packed as completely as possible, a gauze “drip pad” may be taped over the nostrils and changed periodically.

Alternatively, a preformed nasal tampon (Merocel or Doyle sponge) may be used.¹² The tampon is inserted carefully along the floor of the nasal cavity, where it expands on contact with blood or other liquid. Application of lubricant jelly to the tip of the tampon facilitates placement. After the nasal tampon has been inserted, wetting it with a small amount of topical vasoconstrictor may hasten effectiveness. It may be necessary to drip saline into the nostril to achieve full expansion of the tampon if the bleeding has decreased at the time of insertion. Although one study¹⁵ found no significant difference in patient comfort or efficacy with nasal tampons or ribbon gauze packing, simplicity of placement makes the tampons highly useful in primary care settings. When applied in the outpatient setting, nasal packing may be left in place for three to five days to ensure formation of an adequate clot.¹²

Complications of nasal packing procedures include septal hematomas and abscesses from traumatic packing, sinusitis, neurogenic syncope during packing, and pressure necrosis secondary to excessively tight packing. Because of the possibility of toxic shock syndrome with prolonged nasal packing, use of a topical antistaphylococcal

Complications of nasal packing procedures include septal hematomas and abscesses, sinusitis, neurogenic syncope, and pressure necrosis.

The Authors

CORRY J. KUCIK, LT, MC, USN, is a naval flight surgeon and hyperbaric medical officer with Marine Fighter Attack Squadron 251, Marine Corps Air Station, Beaufort, S.C. Dr. Kucik received his medical degree from the Uniformed Services University of the Health Sciences F. Edward Hébert School of Medicine, Bethesda, Md., and completed a family medicine internship at Naval Hospital Jacksonville, Jacksonville, Fla.

TIMOTHY CLENNEY, CDR, MC, USN, is a staff family physician at Naval Hospital, Jacksonville, as well as a naval undersea medical officer. After graduating from the University of South Florida College of Medicine, Tampa, Dr. Clenney completed a family medicine residency at Naval Hospital Jacksonville. He also completed a faculty development fellowship and earned a master of public health degree from Emory University, Atlanta.

Address correspondence to Timothy Clenney, CDR, MC, USN, 1705 Broad Water Ct., Orange Park, FL 32003 (e-mail: tclenney@msn.com). Reprints are not available from the authors.

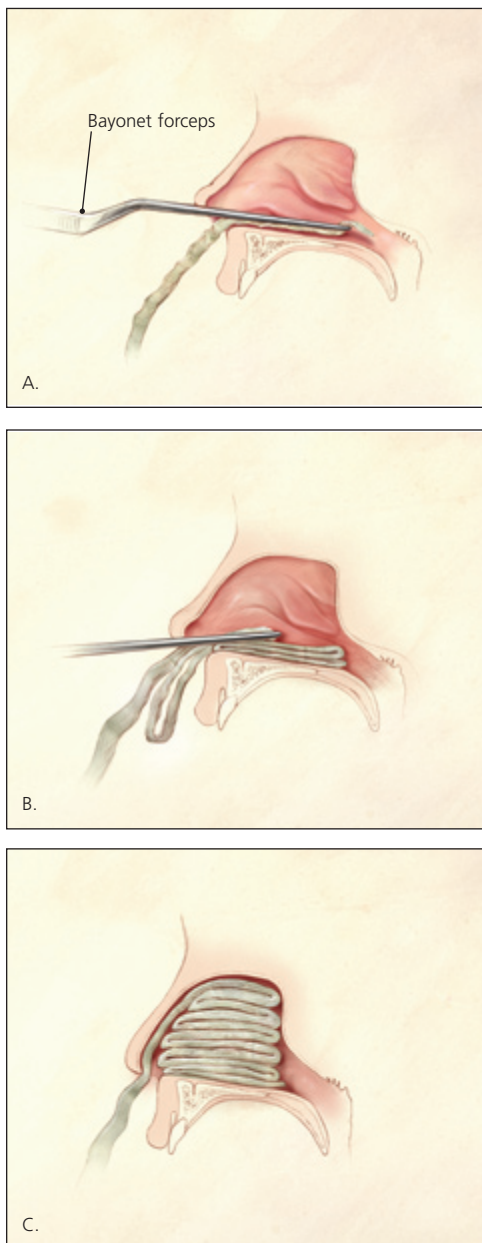


Figure 3. Packing of the anterior nasal cavity using gauze strip impregnated with petroleum jelly. *A.* Gauze is gripped with bayonet forceps and inserted into the anterior nasal cavity. *B.* With a nasal speculum (not shown) used for exposure, the first packing layer is inserted along the floor of the anterior nasal cavity. Forceps and speculum then are withdrawn. *C.* Additional layers of packing are added in an accordion-fold fashion, with the nasal speculum used to hold the positioned layers down while a new layer is inserted. Packing is continued until the anterior nasal cavity is filled.

antibiotic ointment on the packing materials has been recommended.^{10,12}

POSTERIOR EPISTAXIS

Posterior bleeding is much less common than anterior bleeding¹⁶ and usually is treated by an otolaryngologist. Posterior packing may be accomplished by passing a catheter through one nostril (or both nostrils), through the nasopharynx, and out the mouth (*Figure 4*). A gauze pack then is secured to the end of the catheter and positioned in the posterior nasopharynx by pulling back on the catheter until the pack is seated in the posterior choana, sealing the posterior nasal passage and applying pressure to the site of the posterior bleeding.⁵ Although this procedure is not outside the scope of family practice, it requires special training and usually is performed by an otolaryngologist.

Various balloon systems are effective for managing posterior bleeding and are less complicated than the packing procedure. The double-balloon device (*Figure 2*) is passed into the affected nostril under topical anesthesia until it reaches the nasopharynx. The posterior balloon then is inflated with 7 to 10 mL of saline, and the catheter extending out of the nostril is withdrawn carefully so that the balloon seats in the posterior nasal cavity to tamponade the bleeding source. Next, the anterior balloon is inflated with roughly 15 to 30 mL of saline in the anterior nasal cavity to prevent retrograde travel of the posterior balloon and subsequent airway obstruction. An umbilical clamp or other device can be placed across the stalk of the balloon adjacent to the nostril to further prevent dislodgement; the clamp should be padded to prevent pressure necrosis of the nasal skin. Balloon packs generally are left in place for two to five days. As with anterior packing, tissue necrosis can occur if a posterior pack is inserted improperly or balloons are overinflated.

If a specialized balloon device is not available, a Foley catheter (10 to 14 French) with a 30-mL balloon may be used. The catheter is inserted through the bleeding nostril and visualized in the oropharynx before inflation of the balloon.¹⁸ The balloon then is inflated

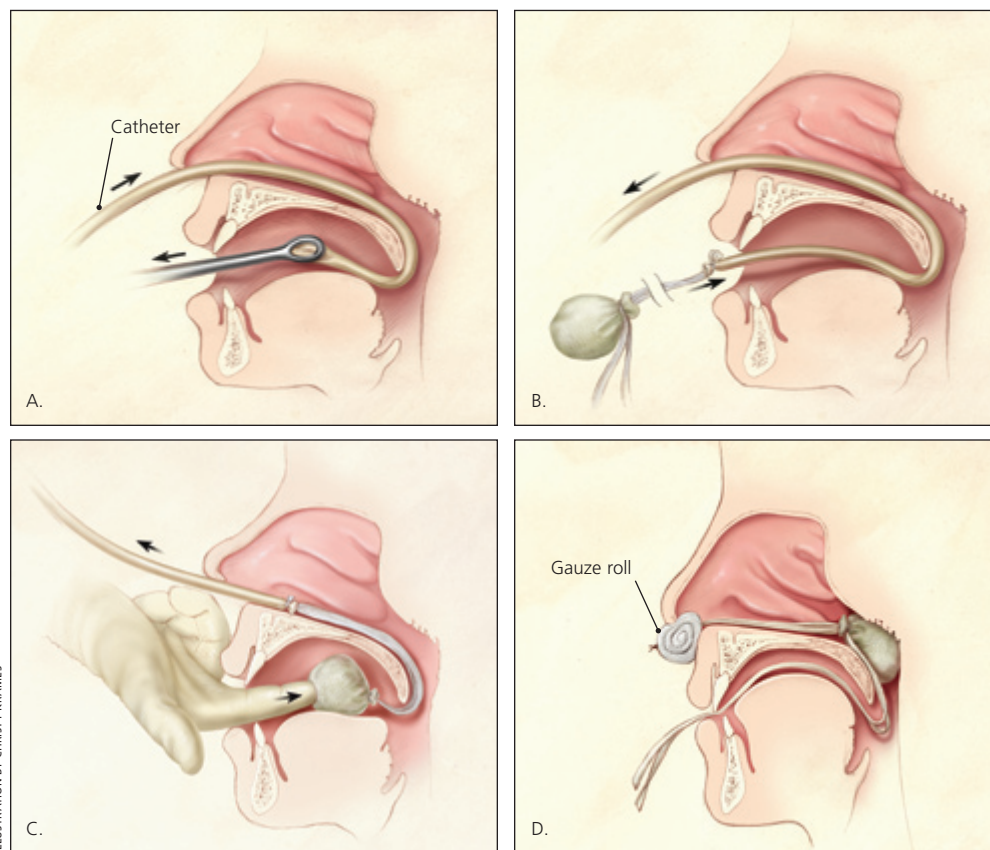


ILLUSTRATION BY CHRISTY KRAMES

Figure 4. Posterior nasal packing. *A.* After adequate anesthesia has been obtained, a catheter is passed through the affected nostril and through the nasopharynx, and drawn out the mouth with the aid of ring forceps. *B.* A gauze pack is secured to the end of the catheter using umbilical tape or suture material, with long tails left to protrude from the mouth. *C.* The gauze pack is guided through the mouth and around the soft palate using a combination of careful traction on the catheter and pushing with a gloved finger. This is the most uncomfortable (and most dangerous) part of the procedure; it should be completed smoothly and with the aid of a bite block (not shown) to protect the physician's finger. *D.* The gauze pack should come to rest in the posterior nasal cavity. It is secured in position by maintaining tension on the catheter with a padded clamp or firm gauze roll placed anterior to the nostril. The ties protruding from the mouth, which will be used to remove the pack, are taped to the patient's cheek.

with approximately 10 mL of saline, and the catheter is withdrawn gently through the nostril, pulling the balloon up and forward. The balloon should seat in the posterior nasal cavity and tamponade a posterior bleed. With traction maintained on the catheter, the anterior nasal cavity then is packed as previously described. Traction is maintained by placing an umbilical clamp on the catheter beyond the nostrils, which should be padded to prevent soft tissue damage. As with anterior epistaxis, topical antistaphylococcal antibiotic ointment may be used to prevent toxic shock syndrome. However, use of oral

or intravenous antibiotics for posterior nasal packing most likely is unnecessary.¹⁹

PERSISTENT BLEEDING

Patients with anterior or posterior bleeding that continues despite packing or balloon procedures may require treatment by an otolaryngologist. Endoscopy may be used to locate the exact site of bleeding for direct cauterization.

Hot water irrigation, a technique described more than 100 years ago, has been reexamined recently. This technique has shown promise in reducing discomfort and length

of hospitalization in patients with posterior epistaxis.^{20,21} More invasive alternatives include arterial ligation and angiographic arterial embolization.

The authors indicate they do not have any conflicts of interest. Sources of funding: none reported.

The opinions and assertions contained herein are the private views of the authors and are not to be construed as official or as reflecting the views of the U.S. Navy Medical Department or the U.S. Naval Service at large.

The authors thank James R. Phelan, CDR, MC, USN, head of otorhinolaryngology at the Naval Aerospace Medical Institute, Pensacola, Fla., for guidance and review of the manuscript.

Members of various family practice departments develop articles for "Practical Therapeutics." This article is one in a series coordinated by the Department of Family Medicine at Naval Hospital, Jacksonville, Fla. Guest editor of the series is Anthony J. Viera, LCDR, MC, USNR.

REFERENCES

- Pollice PA, Yoder MG. Epistaxis: a retrospective review of hospitalized patients. *Otolaryngol Head Neck Surg* 1997;117:49-53.
- Petruson B. Epistaxis. A clinical study with special reference to fibrinolysis. *Acta Otolaryngol Suppl* 1974;317:1-73.
- Schaitkin B, Strauss M, Houck JR. Epistaxis: medical versus surgical therapy: a comparison of efficacy, complications, and economic considerations. *Laryngoscope* 1987;97:1392-6.
- Rubin Grandis J, et al. The management of epistaxis. 3d ed. Alexandria, Va.: American Academy of Otolaryngology—Head and Neck Surgery Foundation, 1999.
- Tan LK, Calhoun KH. Epistaxis. *Med Clin North Am* 1999;83:43-56.
- Cassisi NJ, Biller HF, Ogura JH. Changes in arterial oxygen tension and pulmonary mechanics with the use of posterior packing in epistaxis: a preliminary report. *Laryngoscope* 1971;81:1261-6.
- Lucente FE. Thanatology: a study of 100 deaths. *Trans Am Acad Ophthalmol Otolaryngol* 1972;76:334-9.
- Koh E, Frazzini VI, Kagetsu NJ. Epistaxis: vascular anatomy, origins, and endovascular treatment. *AJR Am J Roentgenol* 2000;174:845-51.
- Pond F, Sizeland A. Epistaxis. Strategies for management. *Aust Fam Physician* 2000;29:933-8.
- Smith JA. Nasal emergencies and sinusitis. In: Tintinalli JE, Ruiz E, Krome RL, eds. *Emergency medicine: a comprehensive study guide*. 4th ed. New York: McGraw-Hill, Health Professions Division, 1996:1082-93.
- Adornato SG. Epistaxis: new approach [Letter]. *Otolaryngol Head Neck Surg* 2000;123:524.
- Frazer TA, Hauser MS. Nonsurgical management of epistaxis. *J Oral Maxillofac Surg* 2000;58:419-24.
- Lethagen S, Ragnarson Tennvall G. Self-treatment with desmopressin intranasal spray in patients with bleeding disorders: effect on bleeding symptoms and socioeconomic factors. *Ann Hematol* 1993;66:257-60.
- Toner JG, Walby AP. Comparison of electro and chemical cautery in the treatment of anterior epistaxis. *J Laryngol Otol* 1990;104:617-8.
- Corbridge RJ, Djazaeri B, Hellier WP, Hadley J. A prospective randomized controlled trial comparing the use of Merocel nasal tampons and BIPP in the control of acute epistaxis. *Clin Otolaryngol* 1995;20:305-7.
- Viducich RA, Blanda MP, Gerson LW. Posterior epistaxis: clinical features and acute complications. *Ann Emerg Med* 1995;25:592-6.
- McFerran DJ, Edmonds SE. The use of balloon catheters in the treatment of epistaxis. *J Laryngol Otol* 1993;107:197-200.
- Williams M, Onslow J. Airway difficulties associated with severe epistaxis. *Anaesthesia* 1999;54:812-3.
- Derkey CS, Hirsch BE, Johnson JT, Wagner RL. Posterior nasal packing. Are intravenous antibiotics really necessary? *Arch Otolaryngol Head Neck Surg* 1989;115:439-41.
- Stangerup SE, Dommerby H, Lau T. Hot-water irrigation as a treatment of posterior epistaxis. *Rhinology* 1996;34:18-20.
- Stangerup SE, Dommerby J, Siim C, Kemp L, Stage J. New modification of hot-water irrigation in the treatment of posterior epistaxis. *Arch Otolaryngol Head Neck Surg* 1999;125:686-90.